

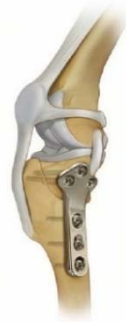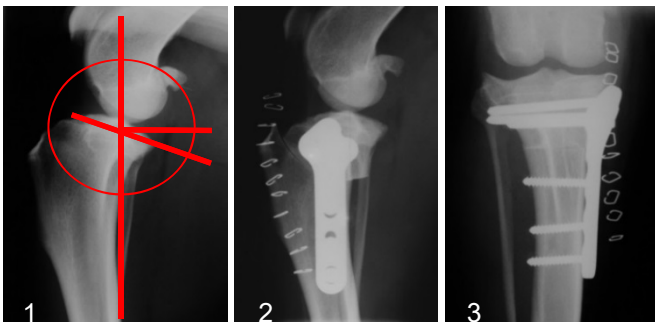
Cruciate Disease in Dogs

RCVS & European Specialists In Small Animal Surgery

Background There are two cruciate ligaments in the knee (or 'stifle' as we call it in dogs). Disease of the cranial (or anterior) cruciate ligament is one of the most common orthopaedic conditions seen in dogs. In people cruciate ligament (or 'ACL') ruptures are typically seen as acute sporting injuries, in footballers and skiers for example. In dogs it is a little different. In most dogs the condition is a more chronic degenerative condition. The ligament degenerates and gets weaker with time and at some point will start to tear. The signs associated with the initial stages of the condition can be subtle and may be missed – signs such as stiffness on rising from rest and mild, occasional lameness. As the ligament continues to tear the signs may become more obvious but it is not uncommon for owners to first realise their dog has a problem when the already damaged ligament finally tears completely, often during relatively normal activity. At this stage the knee will be unstable – the two bones of the stifle (the tibia and femur) will rock back and forth during walking. This instability will often lead to the menisci (cartilage 'shock absorbers' of the knee) being torn.

Diagnosis The diagnosis is often made on palpation/manipulation of the stifle, although in some dogs this may require sedation. X-rays will show signs of osteoarthritis (OA or 'arthritis'). Early cases may be less easy to diagnose, sometimes requiring exploratory surgery/arthroscopy to visually examine the cruciate ligament.

Treatment Small dogs (less than 15kg) may do well with a period of rest and antiinflammatories alone, although surgery may offer a quicker recovery. Larger dogs are unlikely to do well without surgery and so surgery is always advised. Surgery involves examination of the menisci, so that any torn pieces can be removed, and stabilisation of the joint. Numerous stabilisation techniques have been described. Some try to limit the abnormal movement in the knee by placing a restraining suture around the outside of the joint to try to replicate the function of the torn ligament (known as extracapsular suture /lateral retinacular suture or TightRope stabilisation). Unfortunately it is our experience that these techniques often result in recurrent instability, especially in larger dogs. A different strategy is to change the geometry of the tibia to counteract the forces that cause the instability. In this way the knee becomes much more stable but is not reliant on a suture that can stretch or break. Two such techniques are tibial plateau levelling osteotomy (TPLO) and tibial tuberosity advancement (TTA). Both techniques can work well but research studies and our experience indicate that TPLO provides better stability and a more reliable outcome than TTA. We have seen catastrophic complications following some forms of the TTA procedure performed by general practitioners and we would urge owners to choose their surgeon carefully.



TPLO

1. Preoperative planning: calculation of the tibial plateau angle & osteotomy placement.
- 2 & 3. Postoperative x-rays

